

SUMMARY

In summary, newer management methods for DVT employ regional catheter-based techniques with the aim to achieve better early & long-term results. These methods should be increasingly considered for young, mobile patients who wish to live a better and active life ahead. Vein angioplasty and stenting may also be required in 20%–30% of these patients who have vein stenosis or compression (May Thurner syndrome).



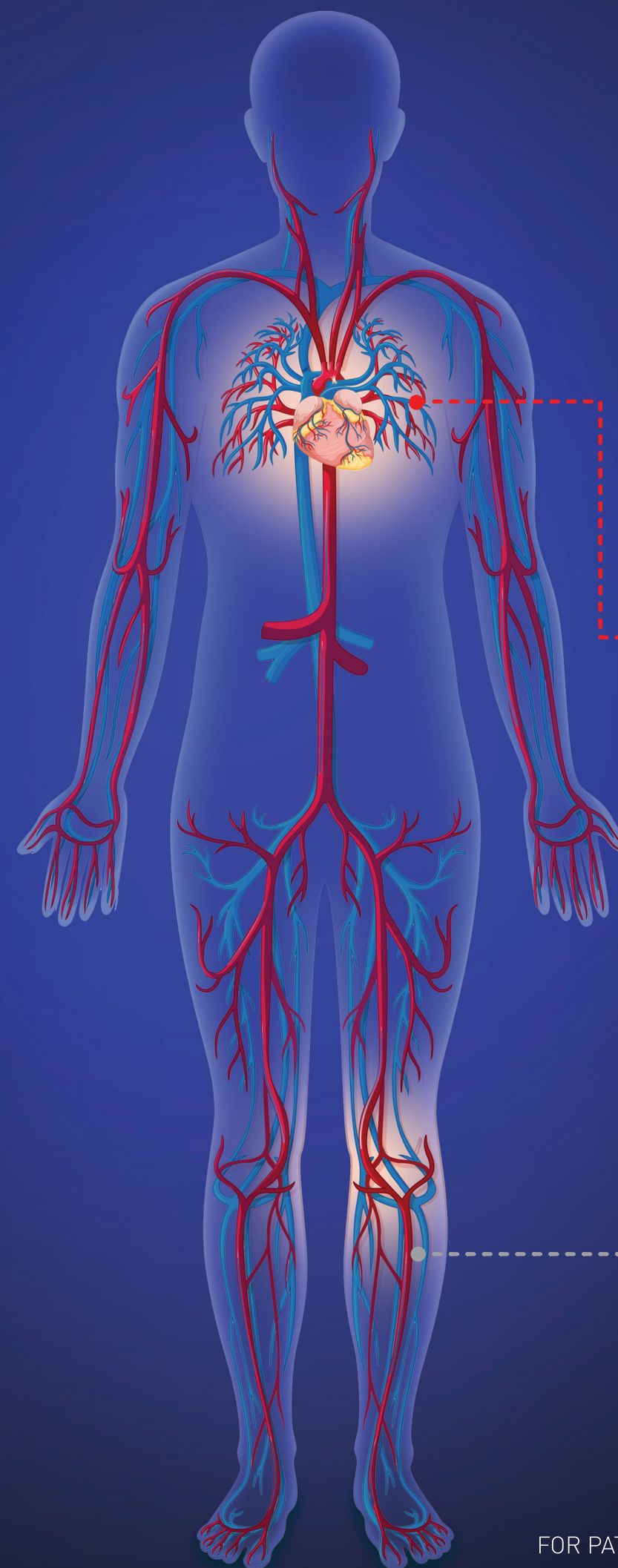
Vascular Society of India

Web: www.vasularsocietyofindia.com

Disclaimer: This material is for informational and educational purposes only. It does not replace the advice or consultation of a doctor or health care professional. VSI makes every effort to provide information that is accurate and timely, but makes no guarantee in this regard. If you think you may be suffering from any of these medical conditions you should seek immediate medical attention. You should never delay seeking medical advice, disregard medical advice, or discontinue medical treatment because of information on this website/ leaflet.



Vascular Society of India



ACUTE LOWER LIMB DEEP VEIN THROMBOSIS CHANGING CONCEPTS IN TREATMENT

FOR PATIENT INFORMATION / EDUCATION PURPOSES

DEEP VEIN THROMBOSIS



Vascular Society of India

INTRODUCTION

Indians were once believed to be affected very rarely by the dreaded problem of DVT. However, over the past 10–15 years, numerous studies have found that DVT is a common occurrence in Indian patients. Another peculiar finding is that in our country, we often encounter idiopathic acute extensive lower limb DVT in young, otherwise healthy people. According to pooled data from multiple vascular centers across India, 10%–20% of patients with DVT belong to this group.

SYMPTOMS & SIGNS OF DVT

- Can range from asymptomatic mild swelling to an extreme form of sudden-onset swelling of one leg, with tightness and pain.
- If thrombus dislodges from leg veins and reaches the lung (pulmonary embolism), patient can develop breathlessness which at times can be fatal.
- In some patients, extensive DVT can cause leg gangrene due to local ischemia.

CAUSES OF DVT

The three common reasons behind the development of DVT include

- Stasis (slow blood flow) due to immobilization after injury or medical illness.
- Vascular trauma (injury or after surgery).
- Hypercoagulable state (cancer, dehydration, thrombophilia).

DIAGNOSIS OF DVT

- Blood tests: **D-dimer** is an important screening test. **Hematologic blood tests can identify thrombophilic (hypercoagulable) state.**
- Doppler: Color doppler can detect DVT with fair accuracy.




Figure 1: Colour Doppler

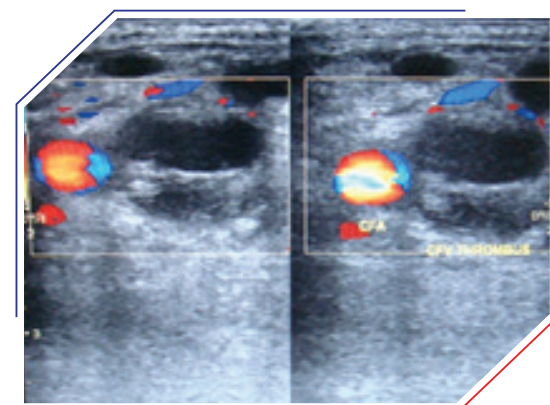


Figure 2: Colour doppler outlining the thrombus

MEDICAL TREATMENT

The initial treatment of DVT is by use of injectable anticoagulants like heparin or low-molecular weight heparin (LMWH) followed by oral anticoagulation using warfarin or newer oral anticoagulants. These oral medicines are usually continued for 6-9 months. Along with this, stockings may be used to control leg swelling.

MODERN TREATMENT

Despite using the same medical treatment methods, the response to treatment is noted to be different in few patients. About 20%–30% of young patients with DVT end up with persistent swelling of limbs. In the long term, **post-thrombotic syndrome (edema, pigmentation, ulcers, lipodermatosclerosis) may be detected in these patients due to chronic thrombosis of veins or associated valvular damage within the veins and incompetence or reflux of blood.**

Worldwide, vascular specialists dealing with acute DVT and its acute as well as chronic problems evaluated newer methods to improve vein recanalisation and also reduce the occurrence of vein valve damage and the incidence of post-thrombotic syndrome. **Catheter-directed treatment methods are now considered to be most effective in achieving these goals. This treatment is a percutaneous, minimally invasive method** performed through the popliteal or femoral vein. After removal of thrombus from the vein by guiding catheter or mechanical thrombectomy devices (Angiojet, Penumbra), direct clot dissolving medicines (thrombolytics) are given for some time to clear the thrombus. If there is vein stenosis/narrowing noted in common iliac vein or IVC, angioplasty with stent placement may also be required.

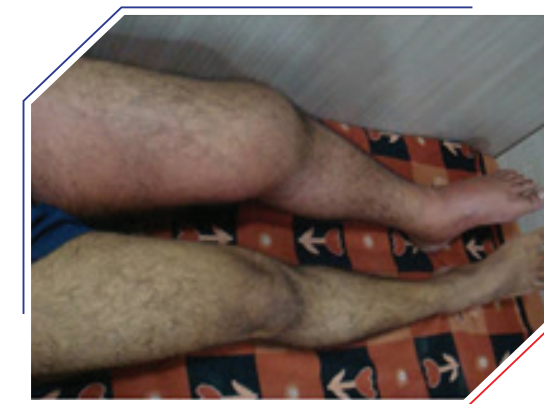

Figure 3. Patient with DVT before procedure

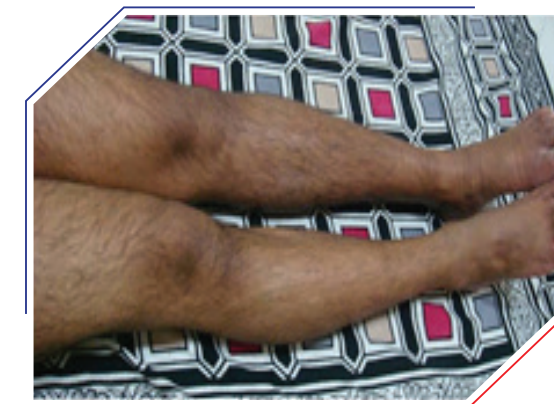

Figure 4. Patient with DVT post procedure

In few patients who are at high risk of pulmonary embolism, an **IVC filter** is placed via the percutaneous route for protection.